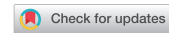

<https://doi.org/10.33878/2073-7556-2025-24-4-81-91>



Laser therapy for wounds after open hemorrhoidectomy (a single-center prospective randomized study)

Salimat G. Magomedova¹, Dmitry V. Vyshegorodtsev¹, Armen V. Vardanyan¹,
Alexandr M. Kuzminov¹, Vyacheslav Yu. Korolik¹, Alina R. Melkumyan¹,
Maria A. Ignatenko¹, Arseniy N. Ryndin¹, Irina V. Vorobyova²

¹Ryzhikh National Medical Research Center of Coloproctology (Salyama Adilya st., 2, Moscow, 123423, Russia)

²Federal Research Center for Epidemiology and Microbiology named after the honorary academician N.F. Gamaleya, Ivanovsky Institut of Virology (Gamaleyi st., 18, Moscow, 123091, Russia)

ABSTRACT AIM: to assess the effect of laser therapy on wounds healing after open hemorrhoidectomy.

PATIENTS AND METHODS: a single-centre, prospective, randomised study included 86 patients who underwent open hemorrhoidectomy using an ultrasound scalpel. In addition to the standard use of water-based ointments daily from days 1 to 7 after surgery and then once a week until the wounds were fully healed, laser treatment was performed on the wounds in patients in the main group ($n = 46$). Patients in the control group ($n = 40$) received only standard therapy (water-based ointments). Laser treatment was performed using a fibre laser with a wavelength of 970 nm in a non-contact manner with a defocused beam. The beam power was 20 W, the power density was 0.038 W/cm² and the mode was pulsed-periodic (impulse duration 50 ms, pause 100 ms). Each session lasted 4 minutes. Pain intensity was assessed with visual analogue scale (VAS). The rate of wound epithelialisation on the 30th day after and QoL using the SF-36 questionnaire. The microbiome of surgical wounds at various stages of treatment, a microbiological study was studied as well.

RESULTS: on the 30th day after surgery, planimetric and cytological characteristics of wounds corresponded to complete epithelization in 42/46 (91%) patients of the main group and in 7/40 (18%) controls, $p < 0,001$. The pain intensity in the main group already from the 2nd day after surgery was 4 (4; 6) points and was significantly lower than in the control group — 6 (5; 7) points, $p < 0,001$. When comparing the patients' quality of life indicators by SF-36 questionnaire on the 30th day after surgery, significant differences were revealed: physical functioning (PF) — 85 (75; 95) points in the main group, 80 (70; 85) — in the control group ($p = 0.030$); pain intensity (BP): 51 (41; 64) in the main group, vs 41 (22; 51) in the control, ($p = 0.008$); and role functioning conditioned by emotional state (RE) — 100 (66; 100) points vs 66 (17; 67), ($p = 0.002$). Microbiology showed that laser therapy already on the 7th day contributes to a significant reduction of postoperative wound infestation in the patients of the main group compared to the control group, and on the 21st day the difference becomes statistically significant — positive growth was noted in 23/42 (54.8%) patients of the main group and in 38/40 (95.0%) of the control group, $p < 0.0001$.

CONCLUSION: the use of laser therapy for wounds after open hemorrhoidectomy allows to achieve good clinical results in healing time, decreased intensity of pain syndrome, decreased bacterial contamination of wounds, which, in turn, contributes to the improvement of the quality of life of operated patients and shortening of rehabilitation.

KEYWORDS: laser therapy, laser radiation, physiotherapeutic wound treatment, wound healing, combined hemorrhoids, hemorrhoidectomy, ultrasonic scalpel

CONFLICT OF INTEREST: the authors declare no conflict of interest

FOR CITATION: Magomedova S.G., Vyshegorodtsev D.V., Vardanyan A.V., Kuzminov A.M., Korolik V.Yu., Melkumyan A.R., Ignatenko M.A., Ryndin A.N., Vorobyova I.V. Laser therapy for wounds after open hemorrhoidectomy (a single-center prospective randomized study). *Koloproktologia*. 2025;24(4):81–91. (in Russ.). <https://doi.org/10.33878/2073-7556-2025-24-4-81-91>

ADDRESS FOR CORRESPONDENCE: Salimat G. Magomedova, Ryzhikh National Medical Research Center of Coloproctology, Salyama Adilya st., 2, Moscow, 123423, Russia; tel.: +7 (988) 435-49-31; e-mail: magomedova_s98@mail.ru

Received — 23.06.2025

Revised — 01.09.2025

Accepted for publication — 10.11.2025

INTRODUCTION

The history of treatment of various postoperative wounds dates back more than a century. The most important thing in this case is the

development of various methods of treating wound infection, which would significantly facilitate and shorten the postoperative period. This is especially true for patients who have undergone anal canal and perineal surgery.

Severe pain syndrome, bacterial contamination of wounds with intestinal microflora, and long healing times can all complicate the course of the postoperative period and lead to prolonged disability [1–5]. In addition, obviously infected wounds of the perineum with their characteristic healing by secondary tension, prolonged inflammatory reaction, supported by persistent infection, can often transform into long-term non-healing chronic wounds [6–8].

Therefore, the modern approach to the treatment of anal canal and perineal wounds should be comprehensive and contribute to reducing pain, reducing the inflammatory response of tissues, reducing bacterial contamination, and accelerating healing processes. One of these methods that meets all the requirements is laser therapy. However, to date, there are no studies that make it possible to evaluate the effectiveness of laser therapy in the treatment of postoperative wounds of the anal canal and perineum.

AIM

Studied effectiveness and safety of the laser therapy in the treatment of wounds after open hemorrhoidectomy.

PATIENTS AND METHODS

In the period from September 2023 to October 2024, a randomized clinical trial was done to estimate the effectiveness of the laser therapy in the treatment of wounds after open hemorrhoidectomy. The study included patients over the age of 18 with stage 4 combined hemorrhoids who expressed their consent to participate. Patients who had previously undergone anal canal surgery; with acute hemorrhoids; the presence of inflammatory bowel diseases; concomitant diseases of the perianal region and anal canal, as well as the presence of severe somatic diseases in the decompensation stage, were not included in the study. In case of non-compliance with the recommendations and refusal to participate, patients were excluded from the study. The primary endpoint of the study was to determine the rate of

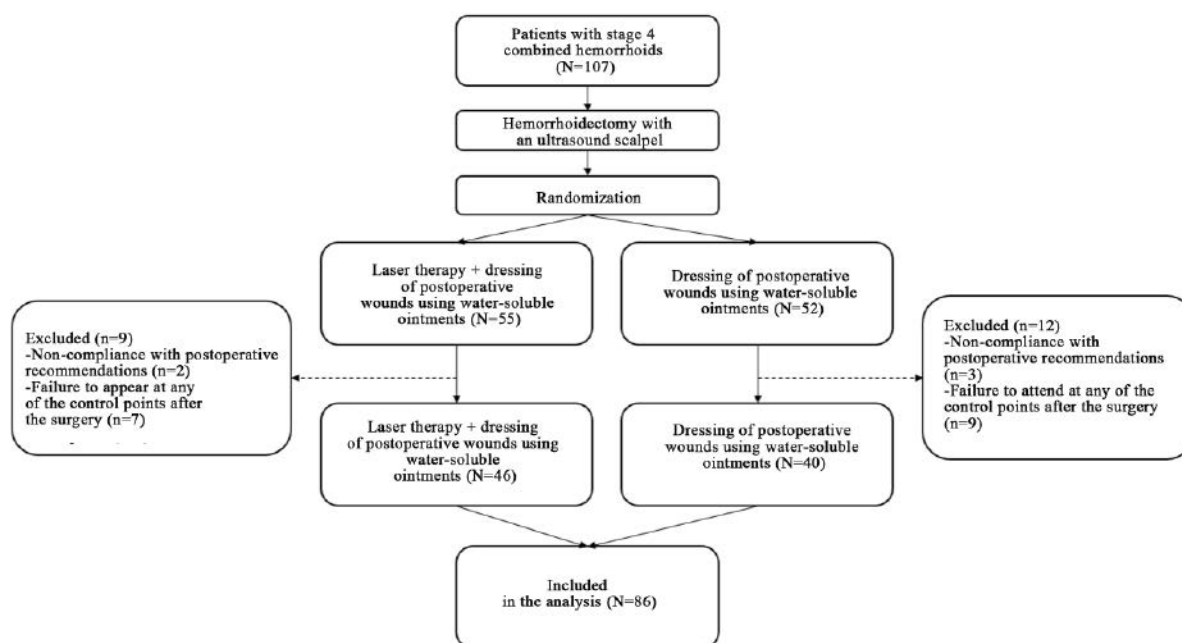


Figure 1. Flow chart of the study

Table 1. General information on patients in the main and control groups

Indicators	Main group N = 46	Control group N = 40
Gender, n (%)	19 (41%)	10 (25%)
Female	27 (59%)	30 (75%)
Male		
Age (years), Me (Q1; Q3)	47 (36; 57)	46 (40; 59)
Min–Max	20–75	28–74
BMI (kg/m ²), Me (Q1; Q3)	27.4 (22.9; 30.1)	25.5 (24.1; 28.8)
Min–Max	17.0–38.9	20.0–33.6
Duration of the disease (years), Me (Q1; Q3)	8 (4; 12)	7 (5; 11)
Min–Max	0–50	0–40
Concomitant diseases, n (%)	20 (43%)	10 (25%)
Hospital stay (days)		
Me (Q1; Q3)	7 (6; 7)	7 (6; 7)
Min–Max	5–30	5–8
Surgery time (minutes)		
Me (Q1; Q3)	20 (15; 30)	25 (18; 30)
Min–Max	8–45	10–45

epithelialization of postoperative wounds on day 30. The severity of the postoperative pain syndrome, the rate of wound healing, microbial contamination of perineal wounds, and the quality of life of patients were assessed as secondary points.

The study included 107 patients with stage 4 combined hemorrhoids who underwent open hemorrhoidectomy with an ultrasound scalpel. After the surgery, patients were randomly assigned to the main (N = 55) and control (N = 52) groups. Due to a violation of the study protocol, namely, failure to attend follow-up examinations, 9 patients of the main and 12 patients of the control group were excluded. Thus, the final analysis included 86 patients: 46 patients in the main group and 40 in the control group (Fig.1). The general characteristics of the patients included in the study are shown in Table 1.

Dressing of postoperative wounds using water-soluble ointments was the basic treatment in the main and control groups. In addition, the patients of the main group were treated with laser radiation daily from the 1st to the 7th days after the surgery and then once a week

until the wounds were completely healed. Laser therapy sessions were performed using a fiber laser with a wavelength of 970 nm. The exposure was performed with a contactless defocused laser beam with a power of 20 W, in a pulse-periodic mode with a pulse duration of 50 ms, a pause of 100 ms, and a power density of 0.038 W/cm². The time of one session was 4 minutes. All patients were examined at various times after the surgery. The pain intensity was assessed using a visual analog scale (VAS) on days 1–7, 14, 21, and 30, and the quality of life was assessed using the SF-36 questionnaire before the surgery and on day 30 after the surgery.

Wound healing was assessed using macroscopic (visual examination, digital examination, anoscopy), planimetric and cytological methods. To determine whether postoperative wounds had an effect on the microbiota at various stages of the treatment, microbiological (culture) studies were performed in all patients on days 2, 7, 14, and 21 after the surgery. The material was taken after the treatment of wounds with saline solution (0.9% NaCl) once in patients of the control group and twice (before and after

Table 2. Pain levels in patients after hemorrhoidectomy

Day after the surgery	Pain intensity (points) Me (Q1; Q3)		p-value
	Main group, N = 46	Control group, N = 40	
1	5 (5; 7)	6 (5; 7)	0.055
2	4 (4; 6)	6 (5; 7)	< 0.001
3	4 (3; 5)	6 (5; 7)	< 0.001
4	3 (3; 4)	5 (5; 6)	< 0.001
5	3 (2; 4)	5 (3; 6)	< 0.001
6	3 (2; 3)	5 (4; 6)	< 0.001
7	2 (1; 3)	4 (3; 5)	< 0.001
14	1 (1; 2)	3 (2; 4)	< 0.001
21	1 (0; 1)	2 (1; 3)	< 0.001
30	0 (0; 0)	1 (0; 2)	< 0.001

the laser treatment) in patients of the main group. The samples of the wound discharge was carried out under conditions of a thermostat, a CO₂ incubator and an anaerobic station, which ensured the growth of obligate-aerobic, facultative-anaerobic and obligate-anaerobic bacteria, as well as fungi. The isolated cultures were identified using a time-of-flight matrix-associated laser mass spectrometer (MALDI-TOF, Bruker, USA). The criteria for positive growth were the detection of microorganisms with a degree of contamination of 10³ or more colony-forming units (CFU).

Statistical Analysis

The information about the analyzed indicators was entered into a relational database in Microsoft Access (Microsoft Office 2021). Statistical data processing was performed in RStudio (R v. 4.4.1 (R Core Team, Vienna, Austria)) using the libraries RODBC, dplyr, gt-summary. All quantitative values were represented as medians, lower and upper quartiles (Me (Q1; Q3)); qualitative values were represented by absolute and relative rates (*n* (%))

or *n/N* (%)). The groups were compared using Wilcoxon's rank sum test for quantitative and qualitative ordinal values; binary qualitative c² Pearson's test for expected values > 10; for lower values, the exact two-way Fisher's test. The differences were considered statistically significant at *p* < 0.05.

RESULTS

The pronounced analgesic effect of the laser therapy was noted from the first days of its use, which was reflected in a decrease in the intensity of pain syndrome from the second day after the surgery in patients of the main group — 4 (4; 6) points, compared with the control group — 6 (5; 7) points, *p* < 0.001.

Also, during the early postoperative period, the pain intensity was significantly lower in patients of the main group, and by day 14 it was characterized as weak (1–2 points), and by day 30 it was absent at all (Table 2).

Another important property of the laser therapy is the stimulation of regeneration processes, which made it possible to accelerate

Table 3. Change in wound area relative to second day

Days after the surgery	Percentage of reduction in wound area compared to the 2nd day, Me (Q1; Q3)		p-value
	Main group, N = 46	Control group, N = 40	
7	4 (3; 7)	3 (2; 4)	0.024
14	31 (27; 39)	18 (12; 25)	< 0.001
21	68 (55; 80)	38 (28; 48)	< 0.001
30	100 (100; 100)	62 (50; 88)	< 0.001

the rate of wound healing. Based on the planimetric method, it was found that in the main group, a decrease in the area of wounds on day 7 compared to day 2 occurred by 4% in the main group, and by 3% in the control group, $p = 0.024$. On day 14, also compared with the latter, a decrease in wounds occurred by 31% in the main group and only by 18% in the control group, $p < 0.001$. On day 21 — by 68% and 38% in the main and control groups, respectively, in addition, 4/46 (8.7%) patients in the main group had complete wound healing. On day 30, wounds healed in 42/46 (91%) patients in the main group and only in 7/46 (18%) patients in the control group, $p < 0.001$ (Table 3).

To assess the effect of the laser therapy on the epithelialization process, a comparative analysis was conducted between the groups based on cytological studies. The type of cytogram

was determined by the severity of the inflammatory reaction and the cellular composition of the smear-imprints. On the 2nd day after the surgery, both groups were characterized by a pronounced neutrophilic inflammatory reaction with the presence of extracellularly and intracellularly located microflora (Fig.2).

On day 7, in patients of both groups, the cytogram mainly corresponded to the inflammatory type, that is, elements of neutrophilic inflammation, blood elements, leukocytes, single histiocytes and fibroblasts prevailed. In the main group, fibroblasts were detected in 4/46 (8.6%) patients, in the control group — in 2/40 patients (5.0%), $p = 0.7$ (Fig.3).

With the transition of wounds to the proliferative phase, the content of histiocytes and fibroblasts increases in smears. So, on day 14, 28/46 (60.8%) patients of the main group had

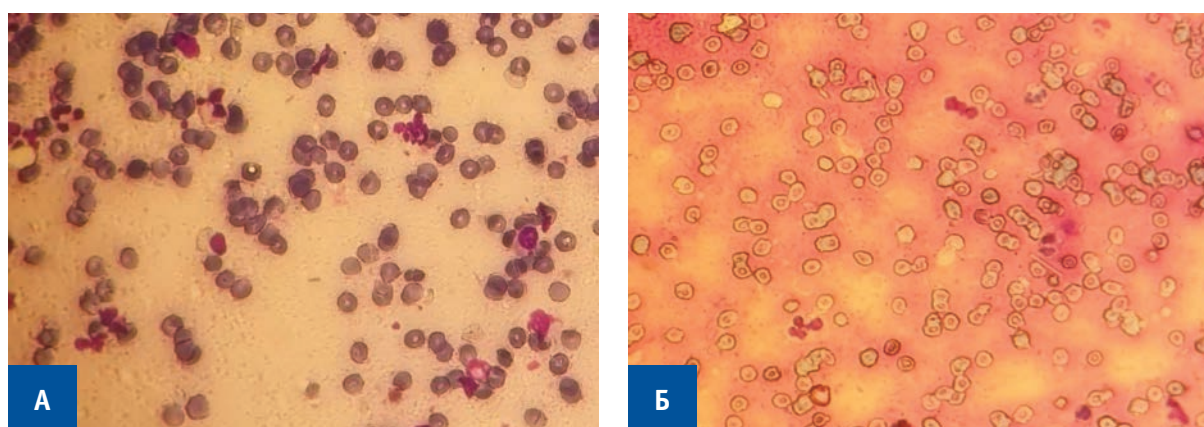


Figure 2. Cytologic picture on the 2nd day after surgery. A) Main group. Patient N., 46 years old. Cytogram is represented by blood cell elements, single leukocytes. Papanheim staining $\times 400$; Б) Control group. Patient K., 45 years old. Cytogram is represented by blood cellular elements, single leukocytes. Papanheim staining $\times 400$

fibroblasts in large numbers. In the control group, this type of cells was detected in 8/40 (20.0%) cases, $p < 0.001$ (Fig.4).

The result of the healing process is the appearance and maturation of epithelial cells in the wound, which indicates the onset of the regeneration (reconstruction) phase. On day 21, epithelial cells of varying degrees of maturity were detected in almost half of the patients in the main group — 19/46 (41.3%), it is important to note that 4/46 (8.7%) patients had complete wound healing. In the control group,

signs of the onset of epithelialization were noted only in 8/40 (20.0%) cases, $p = 0.037$ (Fig.5).

Complete epithelialization of wounds on day 30, which was determined by visual characteristics and confirmed by the detection of squamous epithelial cells of varying degrees of maturity, was observed in 42/46 (91.0%) patients in the main group and only in 7/40 (18.0%) patients in the control group, $p < 0.001$ (Fig.6). Consequently, laser radiation affects all phases of the wound process, which is confirmed

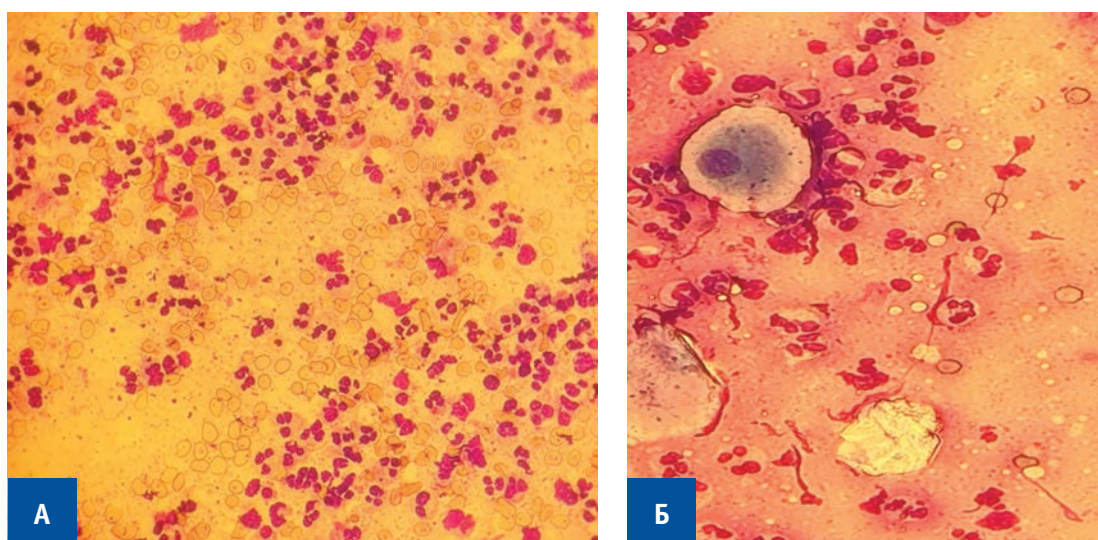


Figure 3. Cytologic picture on the 7th day after surgery. A) Main group. Patient N, 46 years old. Cytogram is represented by neutrophilic inflammatory elements, histiocytes. Pappenheim staining $\times 400$; Б) Control group. Patient K, 45 years old. Cytogram is represented by neutrophilic inflammatory elements, blood elements. Pappenheim staining $\times 400$

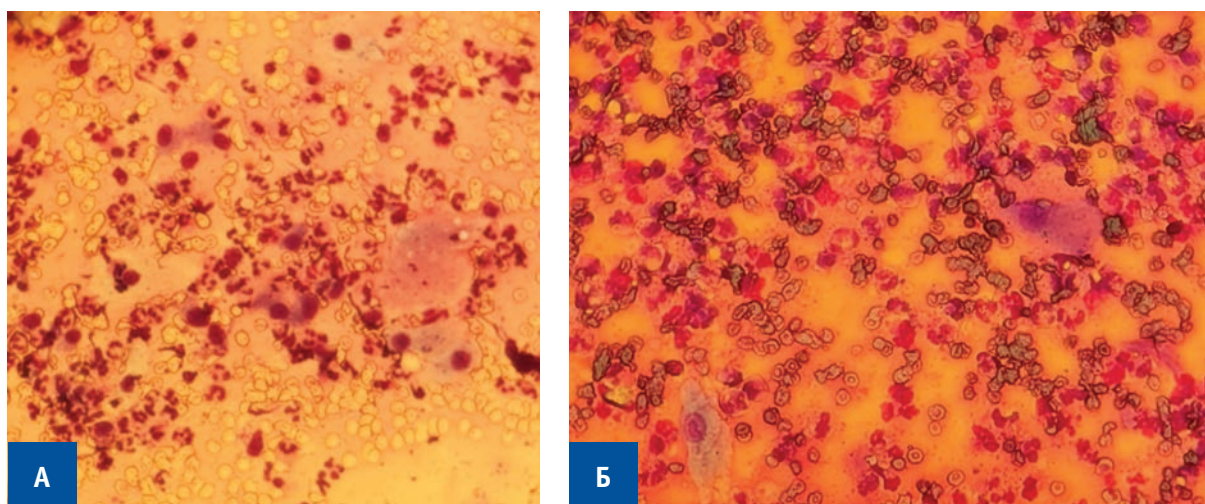


Figure 4. Cytologic picture on the 14th day after surgery. A) Main group. Patient N, 46 years old. Cytogram is represented by neutrophilic inflammatory elements, histiocytes and fibroblasts in large numbers. Pappenheim staining $\times 400$; Б) Control group. Patient K, 45 years old. Cytogram is represented by neutrophilic inflammatory elements, single histiocytes. Pappenheim staining $\times 400$

by a higher rate of epithelialization on day 30 and accelerated healing rates on days 7, 14, 21, and 30. To determine the effect of laser radiation on the microbiota of perineal wounds, the spectrum of microorganisms colonizing the wound surfaces of the perianal region was determined as the first stage. 179 strains of 42 different species of microorganisms were obtained. Facultative anaerobes were predominantly found — 24/42 (57%), obligate anaerobes — 9/42 (21%), obligate aerobes — 7/42 (17%) and fungi — 2/42 (5%).

Subsequently, a comparative analysis was carried out between the groups according to the presence of microbial growth and the degree of bacterial contamination on days 2, 7, 14, and 21.

There were no significant differences between the groups in terms of growth on the 2nd day after the surgery (before exposure to laser radiation): in the main group, growth was detected in 100% of cases (46/46), in the control group — in 92.5% (37/40), $p = 0.097$. Also, the number of isolated species of microorganisms in the group was comparable.: 1 type of microorganisms was isolated from 18/46 (39.1%) patients in the main group and 11/40 (27.5%) in the control group; 2 types — from 18/46 (39.1%) patients in the main group and 10/40 (25.0%) in the control group, 3 types of bacteria were detected in 5/46 (10.9%) patients in the main group and 8/40 (20.0%) — in the control; 4 or more types of microorganisms were detected in 5/46 (10.9%) and 8/40 (20.0%)

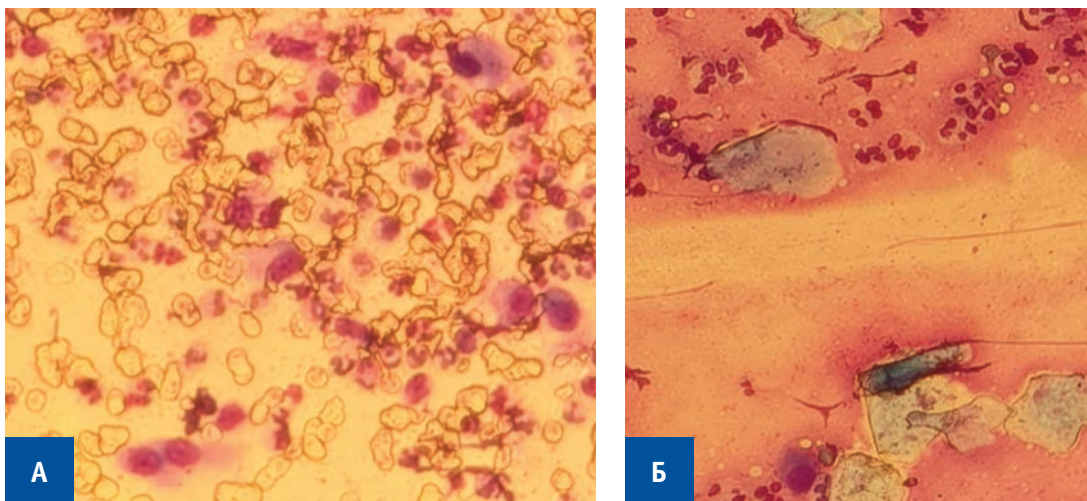


Figure 5. Cytologic picture on the 21st day after surgery. A) Main group. Patient N, 46 years old. Cytogram is represented by single fibroblasts and histiocytes, squamous epithelial cells. Pappenheim staining $\times 400$; Б) Control group. Patient K, 45 years old. Cytogram is represented by inflammatory elements in large amount, histiocytes and single fibroblasts. Pappenheim staining $\times 400$

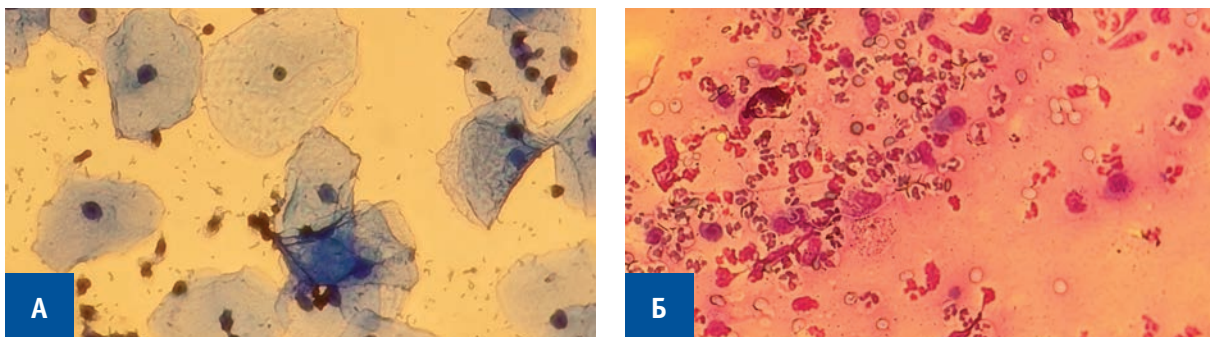


Figure 6. Cytologic picture on the 30th day after surgery. A) Main group. Patient N, 46 years old. Cytogram is represented squamous epithelial cells. Pappenheim staining $\times 400$; B) Control group. Patient K, 45 years old. Cytogram is represented by inflammatory elements in large amount, histiocytes and single fibroblasts. Pappenheim staining $\times 400$

Table 4. The number of sown microorganism species on days 7, 14, 21

Number of types of microorganisms, n	Day 7			Day 14			Day 21		
	MGN = 46 (%)	CG N = 40 (%)	p-value	MGN = 46 (%)	CG N = 40 (%)	p-value	MGN = 42 (%)	CG N = 40 (%)	p-value
0	3 (6.5)	1 (2.5)	0.0053	4 (8.7)	0 (0)	< 0.0001	19 (45.2)	2 (5)	< 0.0001
1	24 (52.2)	9 (22.5)		29 (63.0)	12 (30.0)		15 (35.7)	12 (30)	
2	11 (23.9)	16 (40.0)		11 (23.9)	11 (27.5)		4 (9.5)	15 (37.5)	
3	7 (15.2)	6 (15.0)		0 (0)	9 (22.5)		2 (4.8)	8 (20.0)	
≥ 4	1 (2.2)	8 (20.0)		2 (4.3)	8 (20.0)		2 (4.8)	3 (7.5)	

Table 5. Assessment of patients' quality of life by SF-36 questionnaire before and 30 days after surgery

Indicators	Before surgery			On day 30 after surgery		
	Main group, N = 46 Me (Q1; Q3)	Control group, N = 40 Me (Q1; Q3)	p-value	Main group, N = 46 Me (Q1; Q3)	Control group, N = 40 Me (Q1; Q3)	p-value
PF	90 (65; 100)	90 (78; 98)	0.7	85 (75; 95)	80 (70; 85)	0.03
RP	100 (25; 100)	100 (68; 100)	0.5	63 (25; 100)	38 (0; 75)	0.92
BP	94 (52; 100)	94 (42; 100)	0.7	51 (41; 64)	41 (22; 51)	0.008
GH	71 (45; 77)	77 (50; 77)	0.4	70 (52; 82)	77 (52; 86)	0.4
VT	65 (50; 85)	60 (40; 85)	0.2	65 (50; 75)	60 (50; 75)	0.3
SF	88 (62; 100)	75 (53; 88)	0.061	81 (50; 88)	62 (37; 88)	0.11
RE	100 (33; 100)	100 (33; 100)	1.0	100 (66; 100)	66 (17; 67)	0.002
MH	72 (56; 84)	72 (50; 86)	0.8	76 (64; 84)	70 (58; 86)	0.5

Note: PF — physical functioning; RP — role-physical functioning; BP — bodily pain intensity; GH — general state of health; VT — vitality; SF — social functioning; RE — role-emotional functioning; MH — mental health.

patients of the main and control groups, respectively, $p = 0.095$. Thus, at the start of the treatment, the groups were comparable in terms of the compared indicators. On day 7, after regular laser therapy sessions, positive growth was noted in the main group in 43/46 (93.5%) patients, in the control group in 39/40 (97.5%). At the same time, patients in the main group already showed a significant decrease in

bacterial contamination of wounds compared with the control group.

On the 14th day, the incidence of wounds in patients of the main group was also lower than in the control group.

On day 21, microbial growth was detected in 23/42 (54.8%) patients in the main group and in 38/40 (95.0%) in the control group, $p < 0.0001$. In addition, patients in the main group were more likely to be identified by only

one type of microorganism, while in the control group 2 or more species were more often detected (Table 4).

Thus, it was found that laser therapy helped to reduce bacterial contamination of postoperative wounds.

The analysis of quality of life indicators showed that on day 30, patients in the main group had significantly better indicators in terms of physical functioning (PF), pain intensity (BP), and criteria reflecting role functioning due to emotional state (RE) than patients in the control group (Table 5).

DISCUSSION

Studies by both Russian and foreign authors have shown the effectiveness and safety of laser therapy in the treatment of wounds of various etiologies. The method helps to accelerate wound healing, reduce inflammation and reduce the intensity of pain. So, in a study performed by Tang, D. and co-authors, the effects of the laser therapy were demonstrated, namely, stimulation of wound healing and analgesic effect. The paper compared the results of the treatment of patients with chronic wounds of various etiologies [13]. The results of the study showed a significant reduction in wound healing time in the diode laser treatment group and a decrease in pain levels, which is comparable to the data we obtained, which demonstrate a significant decrease in pain intensity after the first session of the laser therapy in patients in the main group.

Another study also demonstrated the ability of laser therapy to stimulate healing processes, using the example of the treatment of diabetic foot ulcers and non-healing wounds.

The laser therapy served as an additional treatment method and was performed using three lasers of different wavelengths (660, 800 and 970 nm), with an energy of 30 kJ for 3 minutes. The laser radiation contributed to wound healing in 36.6% of cases, and in the

remaining cases, there was a reduction in wounds by 68.2–99% [14]. To achieve maximum effect, the authors used laser radiation of three different wavelengths. In this study, it was demonstrated that the use of a laser of one wavelength (980 nm) is sufficient to stimulate reparative processes, which is reflected in a reduction in wound healing time.

Being an effective physiotherapy method, laser therapy has been used for many years in the treatment of wounds of the anal canal and perianal area. However, to date, there is no consensus on the parameters of the laser device used, the methods of performing wound treatment, as well as the need to combine the laser therapy with other treatment methods.

A number of authors consider it necessary to use different types of laser radiation depending on the phase of the wound process: low-energy ultraviolet radiation in the 1st phase of the wound process and helium-neon radiation in the 2nd phase in patients after surgeries on the anal canal. At the same time, the results of our study indicate the effectiveness of the use of infrared laser radiation throughout the entire period of wound treatment, as evidenced by the accelerated rates of wound healing on days 7, 14, 21 and 30 [9–11].

Kovalev, S.A. et al. used laser therapy as a part of the comprehensive physiotherapy treatment for wounds after hemorrhoidectomy, including intravenous ozone therapy, rectal laser therapy, rectobialmyostimulation, and biofeedback therapy. The results obtained during the study demonstrated the effectiveness of the proposed treatment package [12]. However, in this study it is not possible to assess the degree of direct influence of laser therapy on the results obtained. At the same time, the results obtained during our study allow us to conclude that laser therapy can be used as an independent physiotherapeutic method for treating wounds of the anal canal and perineum.

CONCLUSION

The use of the laser therapy for wounds after open hemorrhoidectomy with the following laser radiation parameters: wavelength 970 nm, power 20 W, power density 0.038 W/cm², pulse-periodic mode with a pulse duration of 50 ms and a pause duration of 100 ms allows achieving good clinical results in reducing wound healing time, reducing pain intensity, reducing bacterial contamination of wounds, which, in turn, contributes to improving the quality of life of those operated on. Thus, laser therapy is an effective, non-invasive method that can be used in the physiotherapy treatment of wounds after surgeries on the anal canal and perianal area.

AUTHORS CONTRIBUTION

Concept and design of the study: *Salimat G. Magomedova, Dmitry V. Vyshegorodtsev, Vyacheslav Yu. Korolik.*

REFERENCES

1. Maistrenko N.A., Romashchenko P.N., Sazonov A.A., et al. Hemorrhoidectomy with the use of modern high-energy devices: advantages, disadvantages and controversial issues. *Bulletin of Surgery named after I.I. Grekov.* 2022;181(4):98–105. (in Russ.). doi: [10.24884/0042-4625-2022-181-4-98-105](https://doi.org/10.24884/0042-4625-2022-181-4-98-105)
2. Shelygin Y.A., Blagodarny L.A., Titov A.Y., et al. The nature of wound healing after hemorrhoidectomy performed by ultrasound scalpel and traditional methods. *Russian Journal of Gastroenterology, Hepatology, Coloproctology.* 2005;15(1):59–64. (in Russ.).
3. Kostenko N.V., Shomirov S.S., Esin V.I., et al. Wound healing dynamics after hemorrhoidectomy. *Kuban Scientific Medical Bulletin.* 2014;(5):60–66. (in Russ.).
4. Glukhov A.A., Aralova M.V. Pathophysiology of long non-healing wounds and modern methods of wound process stimulation. *News of Surgery.* 2015; №6. (in Russ.).
5. Khmylov L.M. Hemorrhoidectomy by ultrasonic scalpel: Cand. of medical sciences: 14.00.27. M. 2006;p. 124. (in Russ.).
6. Nehrikova S.V., Sukhina M.A., Mainovskaya O.A., et al. Examination and treatment of patients with chronic postoperative wounds of the anal canal and perineum. *Koloproktologia.* 2022;21(1):89–98. (in Russ.). doi: [10.33878/2073-7556-2022-21-1-89-98](https://doi.org/10.33878/2073-7556-2022-21-1-89-98)
7. Potekaev N.N., Frigo N.V., Michenko A.V., et al. Chronic, long-term non-healing ulcers and wounds of the skin and subcutaneous tissue. *Clinical dermatology and venereology.* 2018;17(6):7–12. (in Russ.). doi: [10.17116/klinderma2018170617](https://doi.org/10.17116/klinderma2018170617)
8. Sarkisyan O.G., Razdorov V.A., Andreev E.V., et al. Biochemical mechanisms in tissue regeneration in diabetic foot syndrome. *Medical Bulletin of the South of Russia.* 2024;15(2):69–75. (in Russ.). doi: [10.21886/2219-8075-2024-15-2-69-75](https://doi.org/10.21886/2219-8075-2024-15-2-69-75)
9. Titov G.M. Treatment of postoperative wounds in proctology using laser radiation: abstract of thesis for the degree of Candidate of Medical Sciences: 14.00.27. Moscow, 1992;16 p. (in Russ.).
10. Blagodarny L. A., Poletov N.N., Titov A.Yu., et al. Physical methods of treatment of wounds of the posterior canal and perineum. *Russian Journal of Gastroenterology, Hepatology, Coloproctology.* 1995;5(2):83. (in Russ.).

Collection and processing of the material: *Salimat G. Magomedova, Alina R. Melkumyan, Irina V. Vorobyova, Arseniy N. Ryndin*

Statistical processing: *Maria A. Ignatenko, Salimat G. Magomedova*

Writing of the text: *Salimat G. Magomedova, Dmitry V. Vyshegorodtsev, Vyacheslav Yu. Korolik*

Editing: *Salimat G. Magomedova, Dmitry V. Vyshegorodtsev, Armen V. Vardanyan*

INFORMATION ABOUT THE AUTHORS (ORCID)

Salimat G. Magomedova — 0009-0006-0501-4470

Dmitry V. Vyshegorodtsev — 0000-0001-6679-1843

Armen V. Vardanyan — 0000-0001-6781-2458

Alexandr M. Kuzminov — 0000-0002-7544-4752

Vyacheslav Yu. Korolik — 0000-0003-2619-5929

Alina R. Melkumyan — 0000-0002-5494-415X

Maria A. Ignatenko — 0000-0003-1153-4510

Arseniy N. Ryndin — 0000-0001-8755-6148

Irina V. Vorobyova — 0000-0003-1153-4510

11. Madaminov A.M., Toichuev R.M., Ismailov N.N. Treatment of anal canal wounds after hemorrhoidectomy. M., Ismailov N. N. Treatment of anal canal wounds after hemorrhoidectomy. *Bulletin of the Kyrgyz-Russian Slavic University*. 2009;9(1):157–159. (in Russ.).
12. Kovalev S.A., Kotenko K.V. Non-medicamentous technologies in early rehabilitation of patients after hemorrhoidectomy. *Issues of resortology, physiotherapy and therapeutic physical training*. 2021;98(6-2):65–71. (in Russ.). doi: [10.17116/kurort20219806265](https://doi.org/10.17116/kurort20219806265)
13. Tang D, Liu C, Chen X et al. The associations between diode laser (810 nm) therapy and chronic wound healing and pain relief: Light into the chronic wound patient's life. *Wound Repair Regen*. 2023 Mar;31(2):227–232. doi: [10.1111/wrr.13066](https://doi.org/10.1111/wrr.13066)
14. Nair HKR, Chong SSY, Selvaraj DDJ. Photo biomodulation as an Adjunct Therapy in Wound Healing. *Int J Low Extrem Wounds*. 2023 Jun;22(2):278–282. doi: [10.1177/15347346211004186](https://doi.org/10.1177/15347346211004186)